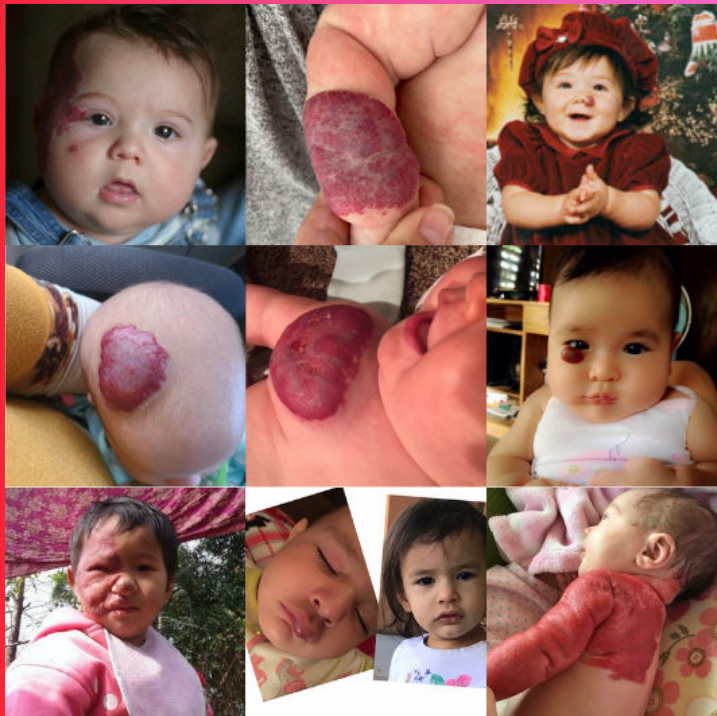



Hemangiomas (Infantile and Congenital) Frequently Asked Questions

Dr. Linda Rozell-Shannon, PhD
President/Founder
Vascular Birthmarks Foundation

Dr. Bernard Cohen, MD
Pediatric Laser Expert

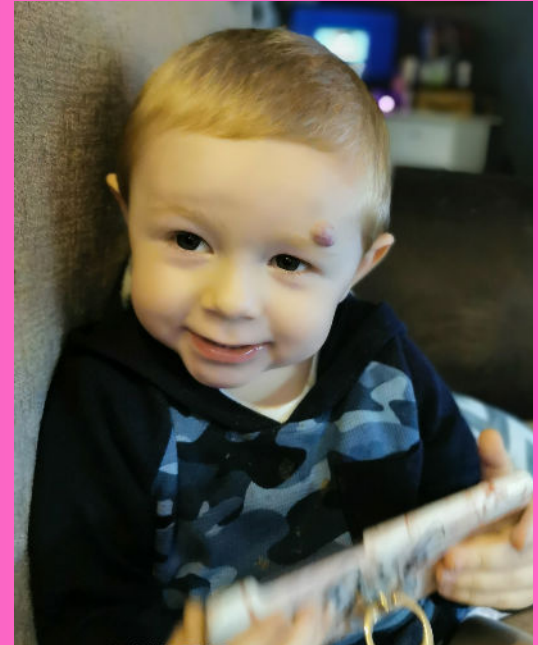Dr. Ana Duarte, MD, FAAD
Pediatric Dermatology Expert

Dr. Milton Waner, MD, MBBCh, FCS(SA)
Hemangioma and Malformations Expert

Section 1: Differentiating Infantile Hemangiomas and Congenital Hemangiomas

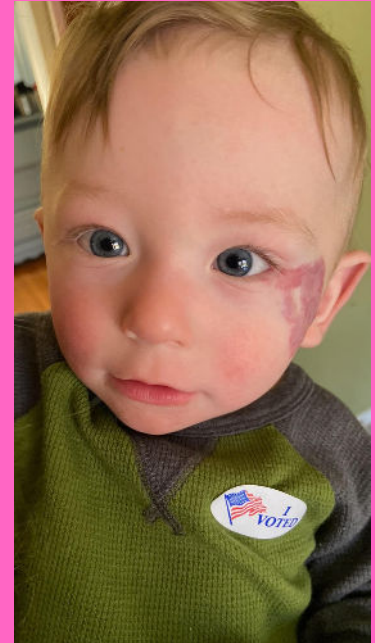Q: What is the difference between an Infantile Hemangioma and a Congenital Hemangioma?

A: An Infantile Hemangioma (IH), for the most part, is not present at birth, though there can be a “pre-warning” outline (light red and subtly elevated) where a deeper, raised hemangioma will soon appear. A Congenital Hemangioma (CH) is fully present at birth, though it can grow a little after birth. It is often picked up on ultrasound during pregnancy. An IH is not visible on ultrasound during pregnancy.



Q: How can I tell which type of hemangioma my baby has? Is there testing?

A: Clinical history is the best way for a parent to know. Was it present at birth? Was it present during the pregnancy? These are the clues. If the clinical findings are not clear, a biopsy and special lab test would confirm the presence of Glut1 which would mean it is definitely an IH. With a CH, the biopsy would be Glut1 negative.

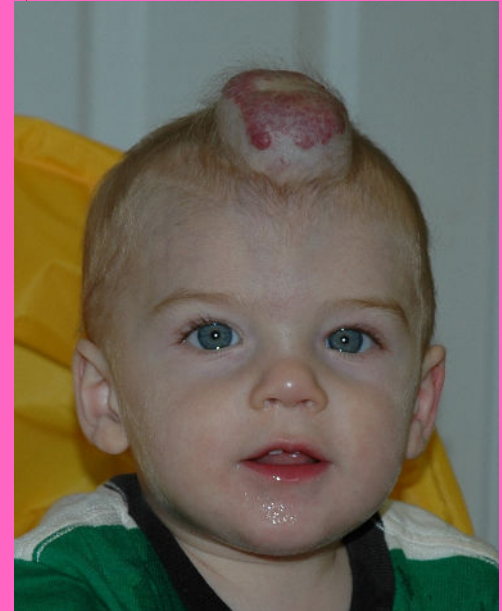

Q: Does treatment differ between IH and CH? If yes, how?

A: Yes, treatment differs. An IH is rarely present at birth but appears shortly after and can require aggressive treatment which includes beta blockers (e.g. oral or topical propranolol), occasionally oral steroids, laser, and sometimes surgery (or any combination). Some IH can actually be left alone and just observed as they are so insignificant. However, since a CH is always present at birth and is frequently quite large, some require emergency intervention, or at least intervention within a month of birth. Some CH can be observed for a while. For example, a RICH (Rapidly Involuting Congenital Hemangioma) is usually observed for a year because it rapidly shrinks without treatment. However, it still may require some form of treatment to reach optimal restoration. The NICH (Non-Involuting Congenital Hemangioma) never regresses so it will likely require intervention, which can be surgery or approaches such as sclerotherapy, embolization, or a combination. Some experts use drug therapy, such as sirolimus. The PICH (Partially Involuting Congenital Hemangioma) only shrinks a certain percent but that can be 20% to 90%. Whatever is left over will need to be removed or treated accordingly.

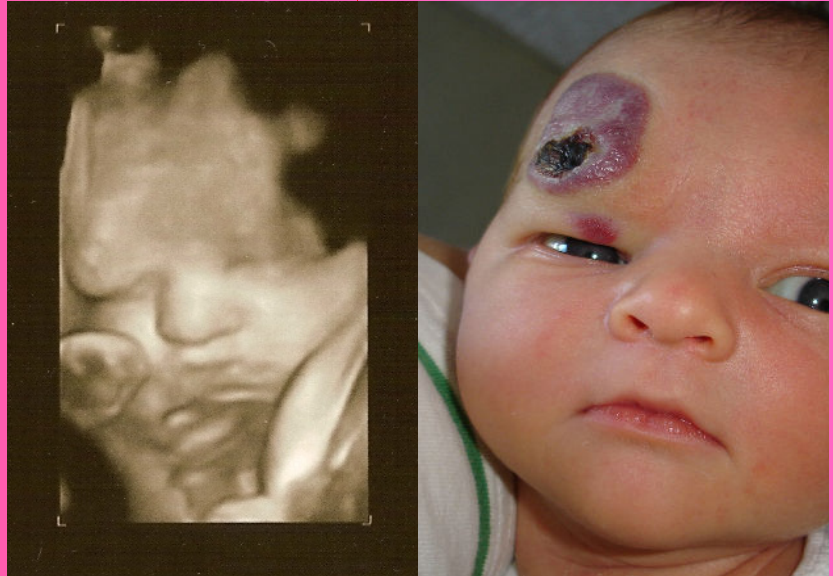Q: What should I do if my doctor is uncertain if it is an IH or a CH?

A: You can ask your doctor to do a biopsy or imaging. Both will help to identify which type of lesion it is. They could also request a consultation from a practitioner with expertise in managing infantile hemangiomas.



Q: Can an Infantile Hemangioma be seen on ultrasound during pregnancy?

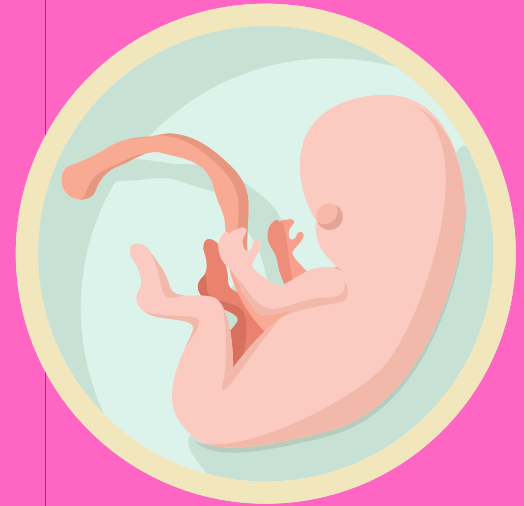A: An IH is not usually seen on ultrasound, but a CH will be seen, for the most part, on imaging.



Congenital Hemangioma

Q: Are placental abnormalities associated with both IH and CH?

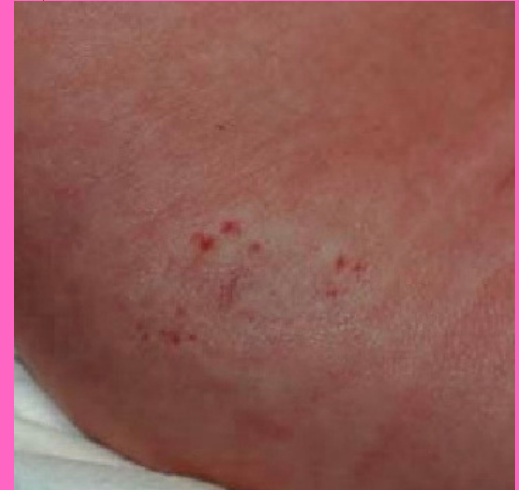A: There has been a lot of research that indicates markers found in the placenta and the IH match. There are also many studies showing mothers of babies with an IH had some sort of placental issue during pregnancy. For these reasons, many experts believe there is some correlation.



Section 2: Presentation and Growth Cycle of Infantile Hemangiomas

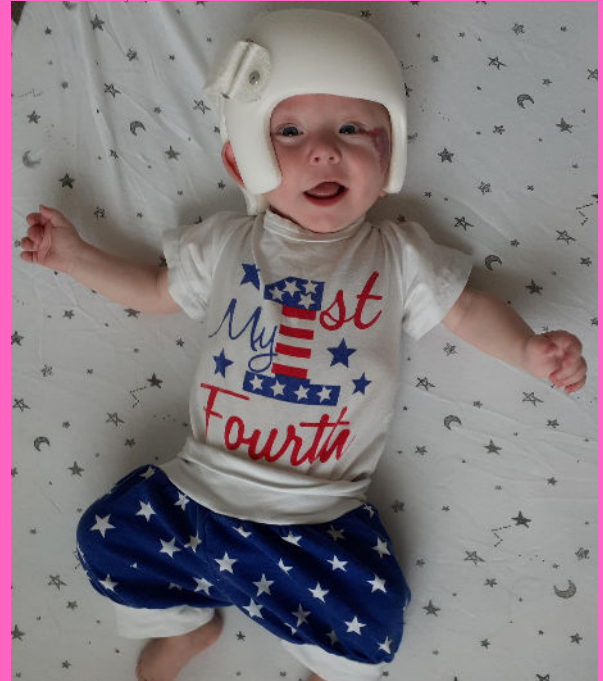Q: When does an IH first appear and what are the treatment options?

A: IH can be a pale halo at birth. Some even look like a white ring or circle within days of the IH turning red. This is usually between birth and the first 2 weeks of life. By two weeks, the pattern of the IH is usually present. Parents should alert their baby's doctor to these observations so that treatment can start as early as 2 weeks of age. If an IH is detected early, when it is still flat or minimally elevated, a topical beta blocker, such as timolol, can be applied to shut down the IH before it grows significantly.



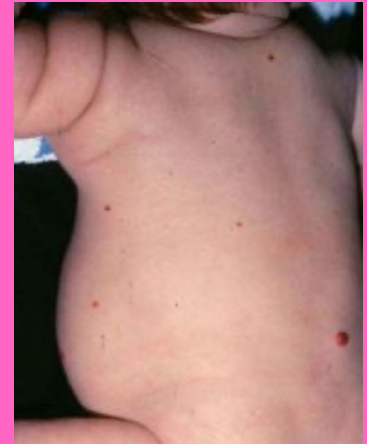Q: Can an IH appear after one week of age?

A: Yes. Most hemangiomas appear at or around the first few weeks of life but some do not become apparent until 3 to 4 weeks, especially the deeper ones. There are deep hemangiomas with no superficial component so many parents just see a bump and don't suspect it is a hemangioma. However, they can be simply deep with nothing red on the surface.



Q: My baby has multiple tiny hemangiomas. Should I be concerned? Should I have any testing done?

A: The rule of thumb by experts is that if there are 5 or more IH, no matter how small or large, the baby should have an abdominal ultrasound to rule out internal lesions, especially liver hemangiomas. Even if there are lesions present in the liver, the baby can be successfully treated. Early diagnosis and treatment is important.



Q: Is an Infantile Hemangioma common, and does it occur more frequently in girls?

A: Statistics vary on the rate of occurrence from 1 in 10 to 1 in 7. However, it has been noted that it is slightly higher in girls and higher in light skinned babies.




Q: How long will a hemangioma grow on my baby?

A: Some hemangiomas stop growing soon after they appear, but this is rare. Most hemangiomas go through a rapid growth cycle of one week to 16 weeks. The IH then seems to go quiet for a few weeks. From about 6 months to a year there can be a little more growth. However, most of the growth occurs within the first 4 months. There are reports of hemangiomas growing past one year, but this is rare.



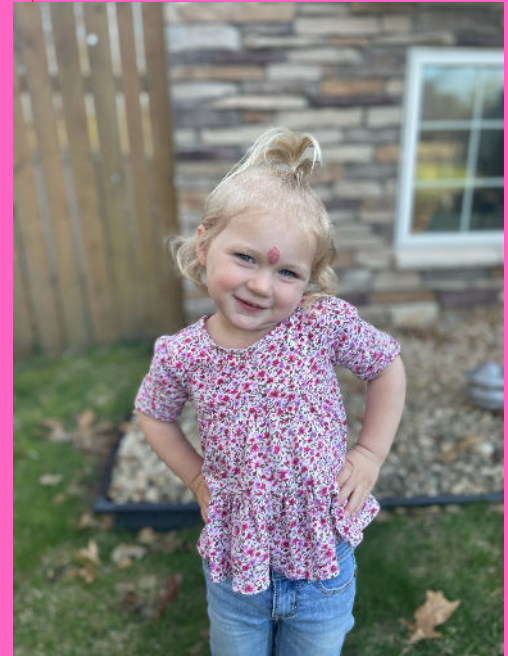Q: Can essential oils be used to treat an IH?

A: The American Academy of Pediatrics has placed warnings on using essential oils on the skin of babies under 3 months old. There is no evidence that any essential oils can effectively treat any kind of hemangioma. Moreover, they can irritate the skin and cause sun sensitivity.



Q: My doctor was pressing on my baby's flat hemangioma to see if it "blanched" (turned white). He said it would help him know if it was a port wine stain or a hemangioma. It did not blanch so he said it was a hemangioma. Is this true?

A: Yes. This is a diagnostic technique used by many experts. A PWS will blanch but an IH won't. If you gently press your finger on the birthmark and hold for one second and remove, you will see if it blanches (turns white) and how quickly it goes back to red. These "signs" are telling.



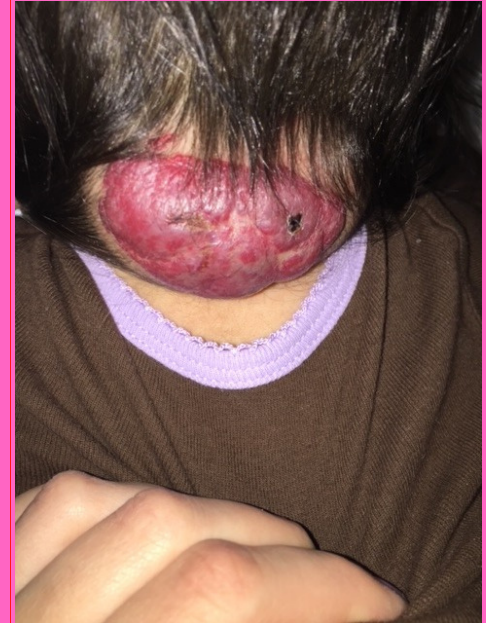Q: What will happen if my baby's hemangioma is bumped and it bleeds?

A: Babies fall, get bumps, cuts, and bruises all the time. A hemangioma, if cut, can be a scary mess. They bleed a lot because they are hyper-vascular. Direct pressure applied to the hemangioma will help the bleeding to stop. A little petroleum jelly and pressure bandage can be applied as well. If it continues to bleed the baby should be taken to the ER or a pediatric Urgent Care.



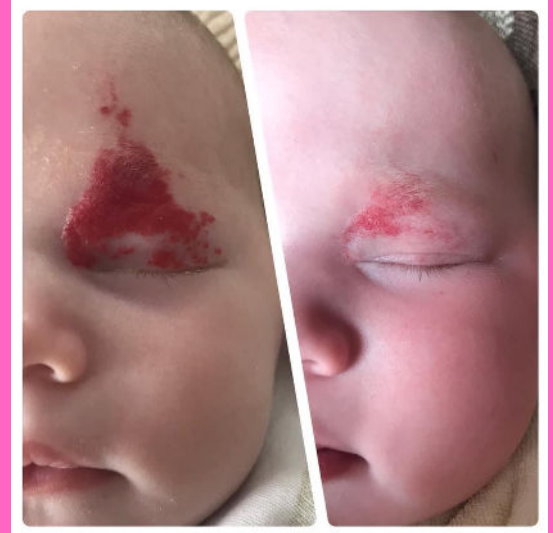Q: My baby's hemangioma ulcerated and is bleeding. She is on a beta blocker but it is still bad. What are my options?

A: Not all babies have a great response to beta blockers. Some require a change or combination therapy. Some experts will add a little bit of oral steroids to the beta blocker, for a short duration, to get the ulcer under control.



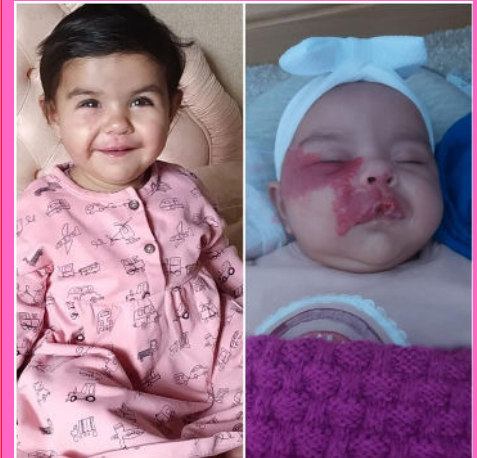Q: My baby's hemangioma is on her eyelid. It's not that big but I'm worried it can affect her vision. Can it?

A: Yes. No matter how big or how small, any lesion on the upper or lower eyelid can result in astigmatism or other eye complications if not treated immediately. The slightest pressure against the globe (eyeball) can reshape it and cause astigmatism. If your baby has an eyelid hemangioma, insist on treatment and insist on getting regular pediatric eye exams.



Q: Half of my baby's face is covered with a hemangioma. My doctor said I should worry about a Syndrome. He wants to do testing. What is that Syndrome and what should I do?

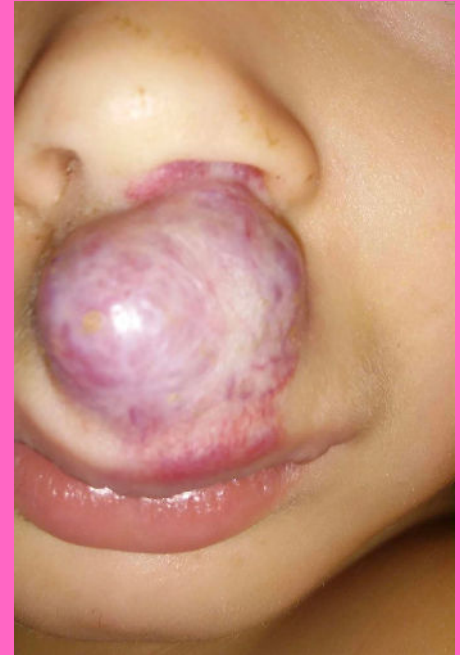A: Your doctor is talking about a syndrome called PHACE Syndrome. Each letter represents a specific area that should be checked for an abnormality: P = Posterior Fossa, H = Hemangioma, A = Aortic Defect, C = Cardiac Defect, and E = Eye abnormalities. You only need an IH plus one other abnormality to have the diagnosis of PHACE Syndrome. If your baby has a segmental hemangioma (includes a large segment of skin on the head and chest area) then ask your doctor to check the baby for PHACE Syndrome. Depending on the location of the IH, testing could include imaging of the brain, heart, and large vessels in the chest.



This is a Segmental Hemangioma, typical for PHACE Syndrome. However, this child was cleared of PHACE Syndrome. Therefore, not all Segmental Hemangiomas are PHACE Syndrome.

Q: My baby is almost 2 years old and the hemangioma is now turning gray. Is that good? What does it mean?

A: When a baby's IH is growing, it is called the "proliferative phase" and when it is shrinking, it is called the "involution phase." The angry red of the IH usually begins to turn a dusky (less angry) color when it is beginning its involution process. So, it is a good sign to see the angry red turn to gray.



Q: After my baby's hemangioma was surgically removed, it grew back. Will that keep happening? Why did it grow back?

A: Sometimes an IH has to be surgically removed because it is a problematic IH. This can be prior to age 1 when the lesion is usually done growing. If it does recur, and this is usually because it was not completely removed, the baby can be put on a beta blocker or have a second surgery to resolve it. If the recurrent hemangioma is not causing problems, and not growing quickly, it can also be left alone to regress on its own, as long as it is not disfiguring and/or problematic.

Q: What is the difference between Superficial and Deep Hemangiomas versus a Compound/Complex Hemangioma?

A: The terminology for an IH (infantile hemangioma) has changed dramatically over the last 3 decades. A “Superficial” Hemangioma is one that is NOT raised up or puffy but is pretty flat and does not involve the deeper skin or fat. A “Deep” Hemangioma is one that is deep but there is no angry red superficial lesion. It just looks like a bump under the skin. Sometimes a blue and/or purple hue is apparent. A Compound/Complex IH is the term usually reserved for an IH that is both deep and superficial. It has a red component on the surface of the skin, and a bulky component beneath the skin.



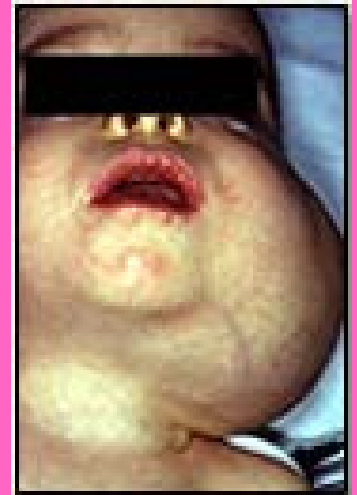Q: Do all hemangiomas have a red surface?

A: No. As previously explained, the “Deep” only IH, will not have any red on the surface. It will look like a bump or swelling with no superficial red on the surface of the skin. It is hard to diagnose as many parents or even some experts might think it is just a bump that will go away quickly. If the bump persists beyond a few weeks, it should be tested, usually by imaging, for a Deep IH.



Q: My baby's hemangioma has no color on it. They are calling it deep. It is in her cheek area and is very puffy. Should we consider surgery or wait for it to shrink on its own? She is 2 years old.

A: This is a very tricky area. Any IH that is deep only or Compound, and is in the cheek area can be tricky because it can involve the facial nerve. It can be called a parotid hemangioma if located down along the jawline. Oral drug therapy should be used prior to considering surgery as the facial nerve may be compromised unless the surgery is done by an IH expert who has experience with monitoring the facial nerve.



Q: I have identical twins. They both have a hemangioma. Are hemangiomas genetic?

A: No gene has been identified, as of yet, for an IH. However, there are many reports of a “familial” component. Many affected families report that other family members have or had an IH.



Q: I keep trying to figure out why my baby developed a hemangioma that appeared two weeks after birth. I had severe toxemia during pregnancy. Does the toxemia have any correlation to the hemangioma?

A: There have been many studies linking placental abnormalities to the IH. Toxemia is associated with high blood pressure, is commonly associated with placental abnormalities, and has been associated with the IH.



Q: My daughter is 20 years old. She had a large hemangioma as a baby. She still has saggy skin hanging on her neck and the side of her face from where it was rather large. Why? What should we do? Will insurance cover treatment this long after birth?

A: Hemangiomas can be quite large and if they are left alone to shrink on their own, they often leave a sack of redundant, hanging, fibro-fatty tissue. It's similar to a 300 lb. person losing 150 lbs. They are often left with sagging skin. These hemangiomas can be quite large and when they regress, or involute, they rarely, very rarely, regress to a point where nothing is visible. It is more common to see leftover hemangioma or minor redundant tissue. At any age, this excess tissue can be surgically removed, or treated with a laser. Most insurance companies will not cover treatment, but a case can be made for it being a birth defect which requires a reconstructive procedure.

Q: I gave birth to 3 children. All 3 had a hemangioma and all 3 were in a different location. If a hemangioma is not genetic, why did all 3 of my babies have one?

A: It is extremely unusual for all of the children of one mother to have an IH, but it can happen. No gene has been found but a “familial” component has been suggested. When a mother has all of her children diagnosed with an IH, blood work should be done to see if a genetic marker can be found.

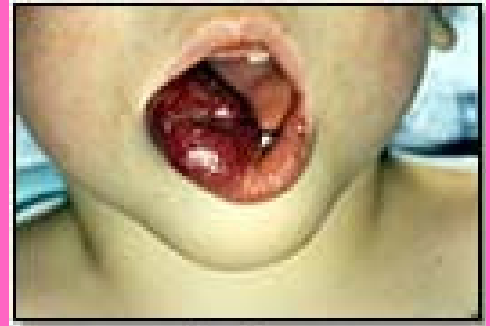

Q: My baby has a hemangioma on her chin and neck. It's very dark red and raised. She is on propranolol but it does not seem to be working. Also, I can see her struggling to breathe at night and she sounds noisy, like she's congested. Is this related to the hemangioma? Can they grow inside her mouth or throat?

A: Yes. The “beard distribution area” for an IH is often suspicious for an airway hemangioma and the baby should be seen by an ENT to rule out airway involvement. The IH can grow in the mouth and in the airway. The noisy sounds at night might be stridor from the baby struggling to breathe around hemangiomas in the airway. Treatment involves using a standard beta blocker and/or laser or some other drug therapy but it should be treated immediately and not left alone.

Q: My daughter's lower lip hemangioma ulcerated. Will it ever look normal? What should we do? She is 18 months old now and has been on Hemangeol for a full year. We didn't start the treatment until after it ulcerated, at about 5 or 6 months of age, as our doctor told us not to treat it.

A: The ulcerated area must be treated first with the proper topicals. By now, most of the growth has stopped. You may have to look at other options such as oral steroids, surgery, laser therapy, continuing with the drug therapy, or a combination of these options. Her lip can resume a good level of normalcy, but you may have to pursue surgery and laser to achieve that goal. This is why it is critical to start Hemangeol or other beta blockers as soon as the hemangioma is emerging.



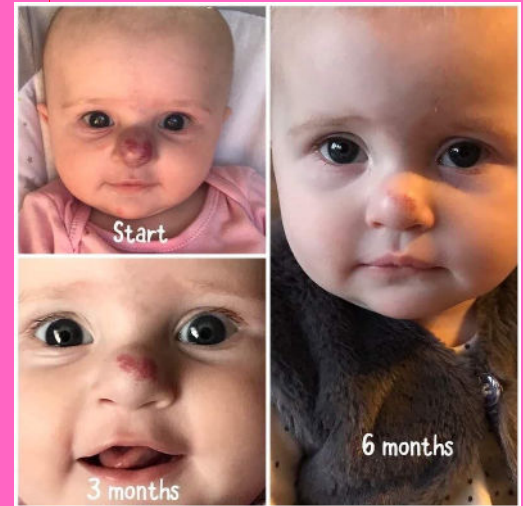Q: I took my baby to two different doctors. One said her birthmark is a port wine stain and the other said it is a hemangioma. How can I know which one it is? It has gotten very dark and raised up since she was born. It also looks a little bit like a scab is forming? She is 4 weeks old.

A: At or shortly after birth, it is often difficult to tell a newly emerging IH from a Port Wine Stain (PWS). However, if you press on it, and it blanches, then it is likely a PWS. Also, an IH will get darker and darker within the first few weeks or months. A PWS will stay the same or even get a little lighter but it does not raise up within the first few months of life. The scab you described may be the beginning of an ulcer and this is more common in a growing IH than a baby with a PWS.



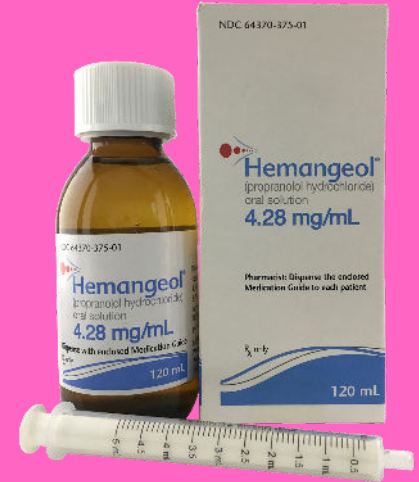Q: My son has a large hemangioma on the end of his nose. Our doctor told us to leave it alone but I have read it can affect his cartilage. He's almost 3 now and it is turning grayish and it feels softer. Should we leave it alone or is there something that can be done so his nose will look normal again?

A: Experts agree that nasal tip IH should be treated aggressively to prevent permanent loss of cartilage. At age 3, the best option is surgery. A vascular anomalies surgeon who has expertise in nasal tip hemangiomas should be consulted. Sometimes a combination of surgery and laser is used to achieve the desired outcome.



Q: When my baby was 4 weeks old her belly got very large. She has over 10 tiny hemangiomas and the doctor said they would go away. Now the doctor thinks they are on her liver and he wants to start her on Hemangeol. Is that the proper treatment?

A: Yes. Hemangeol is the only FDA-approved drug for the treatment of an IH. It is an excellent source. There are other versions of beta blockers as well. The baby should have repeated ultrasounds to ensure the treatment is shrinking the liver lesions. Moreover, if a baby has 5 or more skin hemangiomas, the liver should be evaluated for involvement as soon as possible even if there is no belly enlargement.



Q: Can laser treatments work on a flat hemangioma? The Pediatric Dermatologist we saw wants to use timolol and laser on our infant's newly emerging hemangioma. She is only 6 weeks old. Our Pediatrician said treatment is up to us! We are confused.

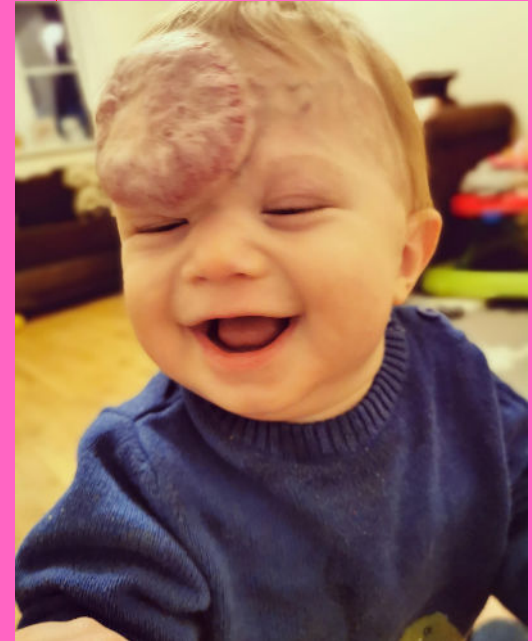A: It is an excellent plan to use topical timolol (a beta blocker) and laser (pulse dye) to treat a newly emerging IH. This early intervention can knock the emerging IH off of its course. Many of our experts use this combined approach. The issue is to get the baby to the expert as soon as the IH is diagnosed and followed closely.



Section 3: Presentation of a Congenital Hemangioma (CH)

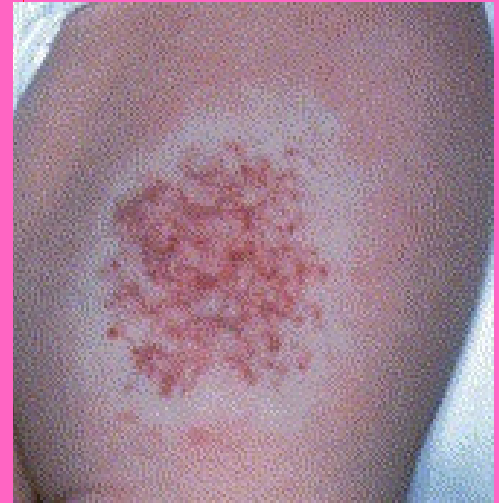Q: Is a CH present in utero? Can it be seen on ultrasound?

A: Yes. A CH is usually present in utero but not every pregnant woman has ultrasounds or sees the CH. It can be missed, depending on the ultrasound, the technician, and the location of the CH. Some can be seen quite clearly. Positioning of the baby in utero is always a factor, plus quality and clarity of the ultrasound imaging.




Q: What are the different types of CH?

A: There are several types of CH. There is the RICH (Rapidly Involuting Congenital Hemangioma) the NICH (Non-Involuting Congenital Hemangioma), and the PICH (Partially Involuting Congenital Hemangioma). Treatment depends on the type. A NICH or PICH will not shrink completely on its own. Often, even a RICH, which will shrink completely, will need surgery to correct leftover redundant tissue.



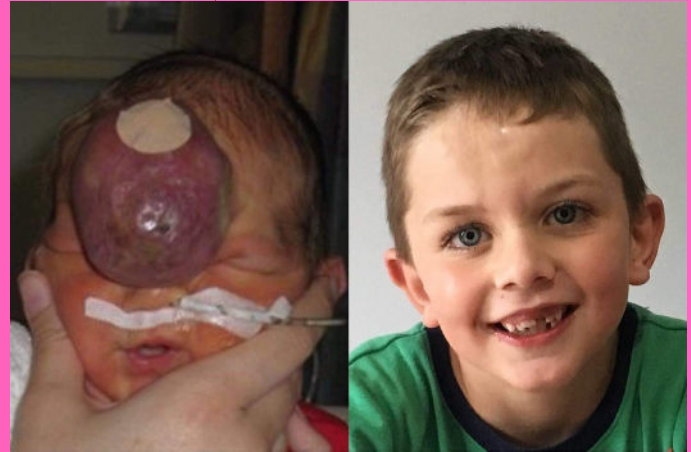Q: How can you tell them apart to know which CH your child has?

A: As explained previously, they can all look similar in utero or even at birth. However, how it “behaves” after birth usually is a sign of which one it is. A RICH will quickly, within weeks of birth, begin to deflate. A PICH will begin to shrink but not as rapidly as a RICH. A NICH will not change at all.



Q: Can a CH go away on its own? How do I know if my baby needs treatment?

A: The RICH can rapidly shrink, but may leave a deformity that will need to be corrected. The PICH has a partial regression, so the remaining lesion will need to be removed. The NICH does not go away on its own.



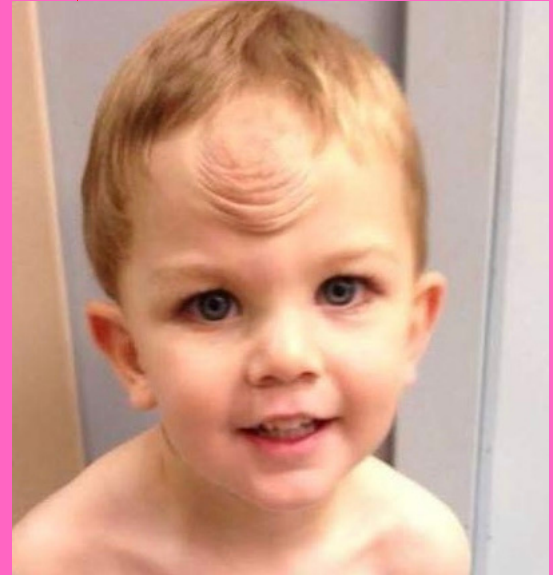Q: My doctor saw a large bump on my daughter's forehead during my 32-week ultrasound. They said it is either an IH or a CH. How can I know which one it is?

A: An IH is not present on ultrasound but a CH usually is. It is likely a CH.



Q: My baby was diagnosed with a RICH. It was the size of an orange at birth and now it looks like a deflated balloon. Will that saggy skin go away or will he need surgery?

A: The redundant tissue left over from a Rapidly Involuting Congenital Hemangioma does not disappear on its own. These lesions (RICH) can regress a great deal, but the majority leave behind some redundant tissue. Therefore, many babies will require some form of surgery to correct the saggy skin.



Q: At 37 weeks gestation, the ultrasound technician saw a large lesion on my daughter's forehead. She said it was some type of hemangioma, and that it may disappear before birth. I gave birth to her at 39 weeks and it was fully present, very large, a dusky color, and had stuff on it that looked fuzzy. The OB/GYN said it will go away on its own but my baby is almost one year old and it has not changed. Help!

A: This sounds like a type of Congenital Hemangioma and if it has not changed at all since birth, and was seen on ultrasound, it is likely a NICH and you should see a surgeon trained in removing these lesions. If it has not shrunk by age one, it likely will not shrink any more.

Q: My Pediatrician said that my baby has an Infantile Hemangioma. It was fully present at birth and was all over her right thigh. She's been on a beta blocker for one year and there has been no change. Could this be a congenital hemangioma? I looked at my 36-week ultrasound and it does look like something is there.

A: This does sound like a CH. You should have a vascular anomalies expert do an ultrasound or other imaging, or even a biopsy to confirm what it is. Since you think you see something on the 36-week ultrasound, it sounds like it is a CH and since there is no response to the beta blocker, that is another indication. She should be taken off of the beta blocker after an ultrasound or imaging or biopsy is done to confirm what it is. She should also have her platelets checked to see if it could be a more problematic type of vascular anomaly that is often called a Hemangioma, but is not an IH or CH.

Treatment Options for Infantile Hemangioma (IH)

Q: What is the best treatment for a small, somewhat flat hemangioma?

A: There are several options for treating a small, somewhat flat hemangioma. You can use topical timolol or laser, or a combination. Some can be left alone to resolve on their own but topical timolol will lighten it and the combo of adding the PDL (Pulse Dye Laser), when done early, can resolve the IH very quickly.

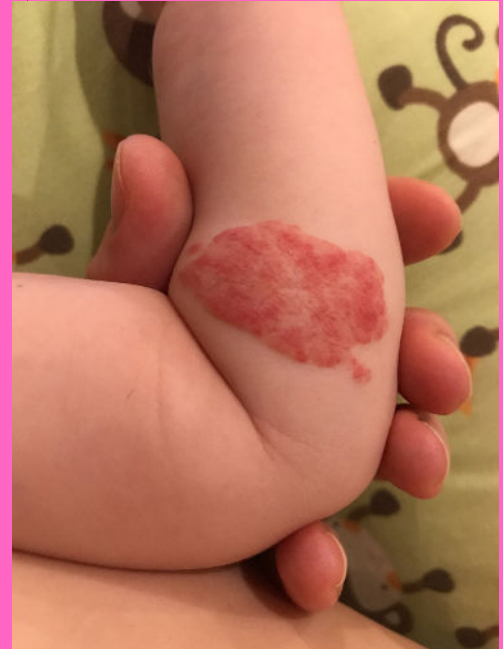

Q: What is the difference between the various beta blockers used for treating hemangiomas?

A: Hemangeol is the ONLY FDA-approved drug for treating an IH. It is a type of beta blocker but its ingredients are more easily tolerated by infants. Many parents report the generic oral suspension is not well tolerated by their infants (they report diarrhea, sleep issues and low blood sugar). Recent reports indicate that since the generic oral suspension contains alcohol and sugar, Hemangeol or another beta blocker should be considered instead. Reports also indicate non-selective beta blockers cross the brain barrier but others (eg atenolol, metropolol, nadalol) do not. Always research a medication before giving it to your infant and if they are having side effects, ask to switch to Hemangeol. Unfortunately, most beta blockers can be associated with sleep disorders, bronchitis, diarrhea, irritability, and hypoglycemia. If these issues occur, consider off-label use of selective beta blockers like atenolol or nadolol.

Q: Is Hemangeol really the only FDA-approved drug for treating IH?

A: Yes. The generic beta blocker propranolol has been used for decades for pediatric glaucoma and pediatric cardiac dysrhythmias and other congenital cardiac issues. It has only been used since 2008 to treat IH.



Q: What happens if my child's hemangioma does not respond to the beta blocker?

A: Not all hemangiomas respond to a beta blocker. They can have the following responses: no response, partial response, or complete response. If your baby is not responding, you could first switch to a different type of beta blocker or change the dosage. If that does not work, you could combine it with steroids. If that does not work, surgery and/or laser should be considered. Typically, if your baby does not respond to a beta blocker ("respond" means it should be lighter, softer, and/or smaller) then they may be intolerant and other options should be explored.



Q: Do beta blockers have any bad side effects? Some of the moms in my support group say I should switch from the oral liquid because it contains alcohol and the pills don't. Is that true? Should I switch?

A: The generic beta blocker does contain alcohol and sugar and this has become a concern. If your baby is having adverse side effects, speak to your doctor about switching the treatment. There are other options: different beta blockers, or adding steroids, laser, surgery, or any combination. Again, selective beta blockers (eg nadolol, metropolol, nadolol), work as well as non-selective beta blockers (generic propranolol and Hemangeol) and have fewer side effects, but they have to be used off-label, since they are not approved for treatment of IH.

Q: Why does my baby's hemangioma keep rebounding after I stop the beta blocker? Should the "stop" be a hard stop or a slow taper? Maybe that's the reason it keeps coming back?

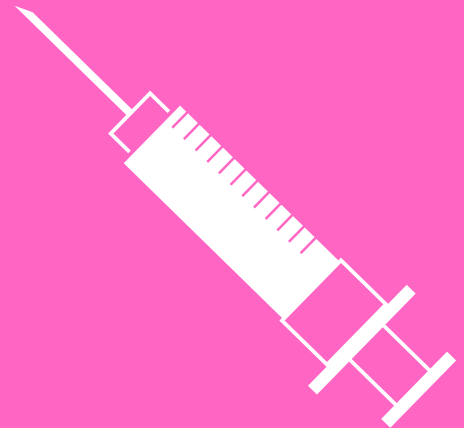
A: Because beta blockers have only been around for treating IH since 2008, we are still learning new things every day. One of the recent observations made by many experts is that if the baby is weaned off too quickly, or if there is a hard stop to taking the drug, then it can rebound. Sometimes even a slow taper will result in rebounding. Some experts are now looking at a taper protocol that will last 30 days for the taper, cutting the dose by 25% each week and observing if there is any rebounding during the taper. Some rebound because they are just plain persistent. Some just need to be treated for a longer period of time and tapered more slowly. If this is not possible, surgical removal and/or other combinations of therapies should be considered.

Q: Can the beta blocker actually cause an ulceration? My baby's hemangioma did not ulcerate until after taking the beta blocker. It looks worse now than before she started treatment. What should I do?

A: Many parents are reporting that their baby's IH got worse after starting the beta blocker. This is being closely studied and observed by experts in the field. Some experts are recommending that if it begins to ulcerate, then a low dose of oral steroids should be added to the routine.

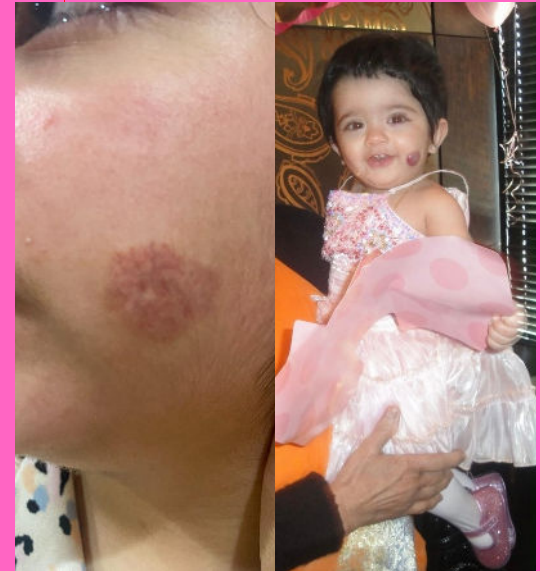Q: Is sclerotherapy or embolization an option for large hemangiomas?

A: There have been successful treatments with both sclerotherapy and/or embolization for very large hemangiomas that are not responding to any drug therapies. These treatments should only be done by a true expert who understands Infantile Hemangiomas.



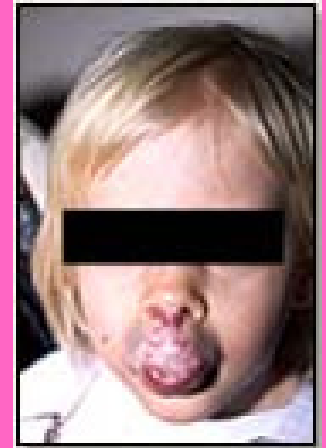
Q: Why is there still some hanging tissue on my baby's face after taking propranolol for 18 months? The hemangioma seems gone but there is the clump of hanging skin. Does that mean the baby will now need surgery?

A: The beta blocker is a revolution in treatment. It has been successfully used to shrink IH since 2008. However, by shrink or involute, it does not mean that the IH will completely disappear. Some experts report that upwards of 60% of all involuted hemangiomas (whether naturally or with drug therapies) will have redundant tissue or telangiectasia that will require surgery and/or laser treatments to correct.



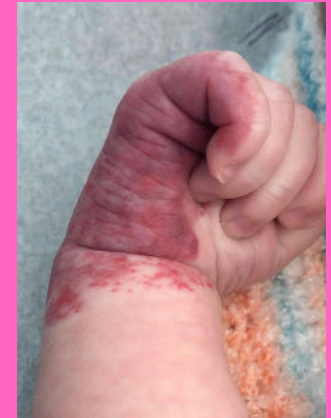Q: We have a baby girl with a large hemangioma on her lip that we chose to not treat. It's lumpy and white and gray looking. Why did this happen? Can it be fixed?

A: Involution means regression or shrinkage. It does not mean that the skin will always resolve to a normal appearance. When an IH fully involutes, the IH is replaced with a fibro-fatty tissue. This tissue can look lumpy and white-grayish on a lower lip. This can be fixed but it will need surgery and/or laser combinations.



Q: My infant son has a very red hemangioma covering almost his entire hand. It looks like he is wearing a red glove. I'm worried it will affect his use of his hand. My husband and I are both right handed and this hemangioma is on our baby's right hand. He's almost one and it is still there, mostly flat but very dark red and some small scabs are on it. Can it still be treated? What are our options?

A: At age one, the growth should be completed for focal (solitary) IH and it should start lightening and softening. Some diffused IH can grow up to 18 months of age. However, you can still try a topical timolol or even an oral beta blocker to see if you can expedite the fading and involution process. You could also try laser treatments, but you should do a test spot first.



Q: Our infant girl is on propranolol for a large hemangioma on the base of her skull. It has severely bled several times and she was rushed to the hospital. They had to do a blood transfusion. She was taking a beta blocker but it did not stop it from bleeding. The doctor wants to add steroids to the propranolol. Is this a good recommendation?

A: Because the baby lays on her head at night and likely moves her head back and forth, during sleep, you should make sure this is covered/bandaged at night. Yes, steroids can be added to the propranolol as well as a tight compression wrapping. If no drug therapy works, this is an example of a large IH that may need either embolization or sclerotherapy or a combination with surgery to remove it.

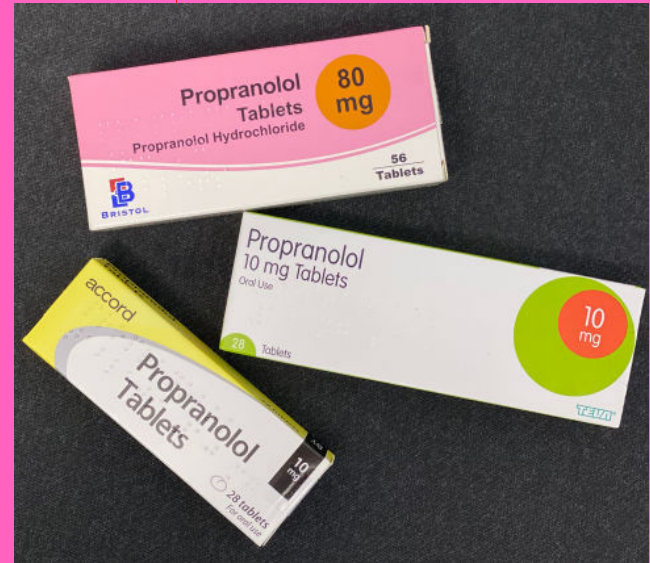Q: The Pediatric Dermatologist diagnosed our daughter with PHACE Syndrome. She has a large facial hemangioma and she has an aortic defect. Will she grow out of this? Should we be watching for other symptoms as she grows up? She is only 2 years old but we worry that she will have other complications down the road, like eye or brain issues. How can we be proactive?

A: PHACE Syndrome is described in another question. It can affect the posterior fossa, the aorta, heart, and/or the eyes. These issues can present any time in life. An expert on PHACE Syndrome should be consulted and should follow your child and any issues that develop should be referred to the expert for consideration as part of the syndrome. There is not a lot of research on patients with PHACE Syndrome that are over 20 or 25 years old, so we are still learning about long-term issues that pop up and seem like they may be related.



Q: My baby was on propranolol for 2 years. Her hemangioma keeps regrowing each time they try to stop the drug. What should we do?

A: Not all hemangiomas “go away” from using the propranolol. You can first check the dosage and see how it compares to the range of 1-3 mg/kg. You can also switch to a different type or add steroids. Also, make sure that the taper is very, very slow. If none of this works, then surgery may be the only remaining option.



Q: Is it normal for children who were on propranolol for over a year to have other issues? My daughter is 3 now and has been off of the drug for 18 months but she keeps having low blood sugar problems and diarrhea for no reason. Could this be related?

A: There are many reports of low blood sugar and diarrhea from parents of babies taking the generic propranolol. If your daughter had these issues during treatment and is still having them, it could be related, although glucose metabolism usually returns to normal over time unless there are other issues triggering the reaction. She should see an endocrinologist for a work up.

Q: What are the long-term side effects of using a beta blocker to treat an IH?

A: Since using a beta blocker for treating IH has only been around since 2008, it is hard to quantify any long-term side effects. Anecdotal information does not indicate any long-term side effects but it may be too early to know for certain.



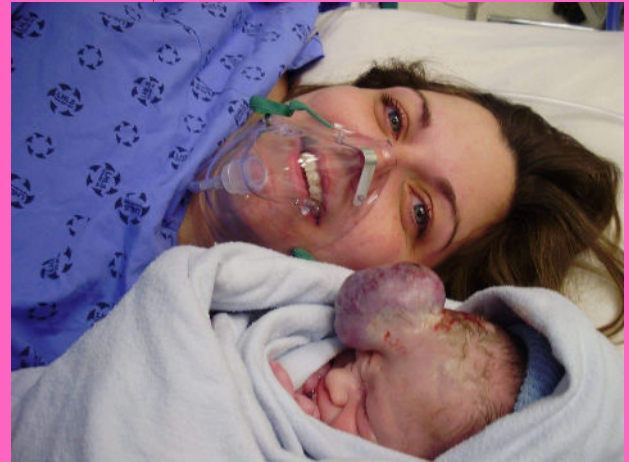Treatment Options for Congenital Hemangioma (CH)

Q: Which CH types require treatment and what are those treatments?

A: Almost all CH types may require treatment. Some of the RICH lesions will completely shrink by 18 months of age but there may be redundant tissue that will need to be resolved. The NICH never regresses on its own, so it needs treatment, as it will never go away if left alone. Treatments for the NICH and PICH have many options and combinations such as surgery, embolization, sclerotherapy and even drug therapies. Each case is evaluated on its own to determine the most effective treatment.

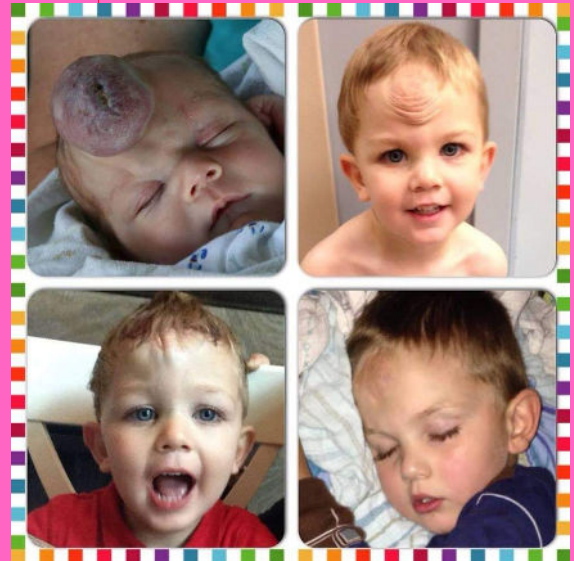Q: Can a CH go away completely on its own?

A: The RICH is the *only* CH that can completely shrink. However, since they are usually quite large at birth, they may leave a sack of redundant tissue after shrinking that will require surgery to remove it. The PICH only partially shrinks so it may require multiple treatment options to remove.



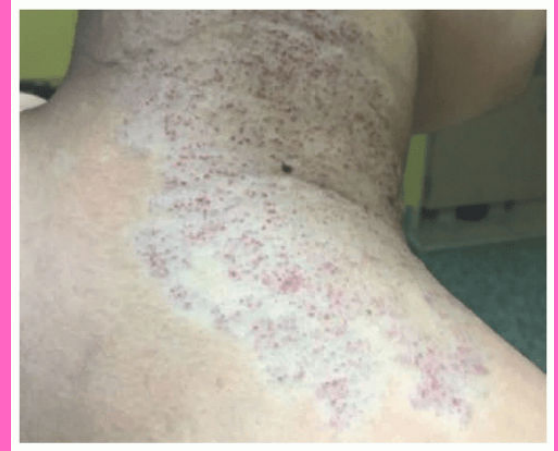Q: If a PICH will never regress fully on its own, why isn't it surgically removed before age 1?

A: Sometimes a PICH will continue to shrink beyond age one so some experts wait until 18 months or 2 years of age before offering surgery.



Q: My child's NICH has flared up and she is 14 years old. Why is it red and firm and growing again?

A: There is not a lot of information on CH that explains why some flare up during puberty, pregnancy or even much later in life. However, parents are reporting flare ups and upon ultrasound there are active vascular lesions. This is one of the reasons why it is important to get an accurate diagnosis and if it is a NICH to try to have it completely removed, if possible, by age one or two. A small biopsy to confirm the diagnosis may be necessary.



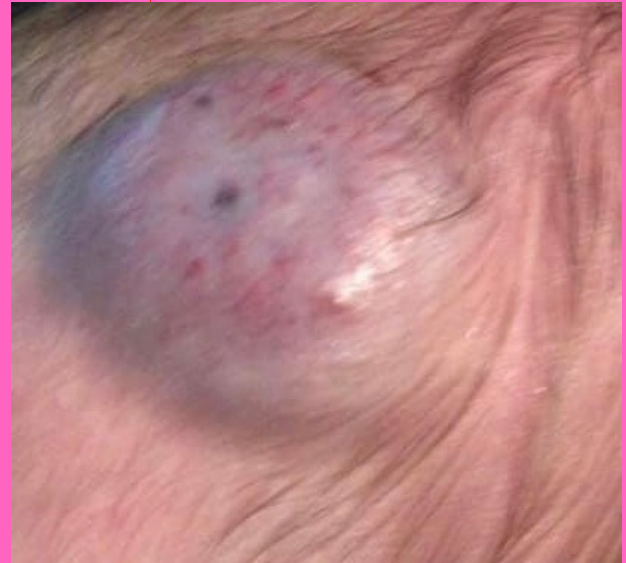Q: My child was born with a RICH and it shrunk a lot but has all of this saggy skin. How do I get rid of that?

A: The best outcome from redundant tissue that remains after a RICH has shrunk is surgical excision. Depending on how much redundant tissue remains, if it is not a lot, sometimes a CO₂ or Fraxel laser can be used to smooth out the skin.



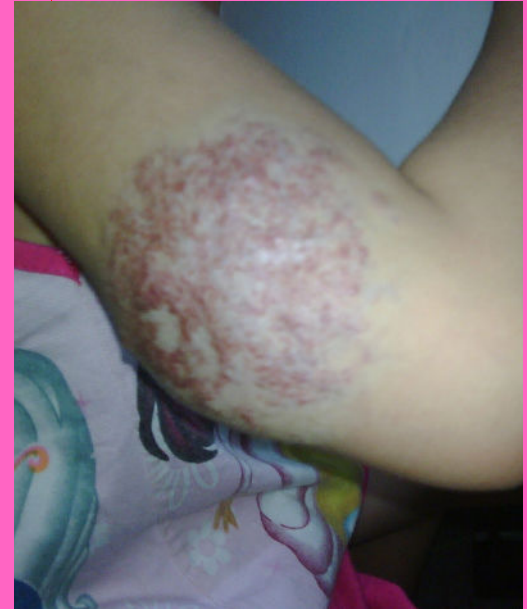Q: My child has a NICH and her Pediatrician put her on propranolol. Why isn't it working?

A: Propranolol is used for an Infantile Hemangioma. It does not work on a Congenital Hemangioma. It is often difficult to tell the difference in infancy but it is well accepted that beta blockers, like propranolol, are not effective on Congenital Hemangiomas.



Q: My baby had her CH removed at age one. She is now 6 years old and it looks like it is coming back. Is that possible?

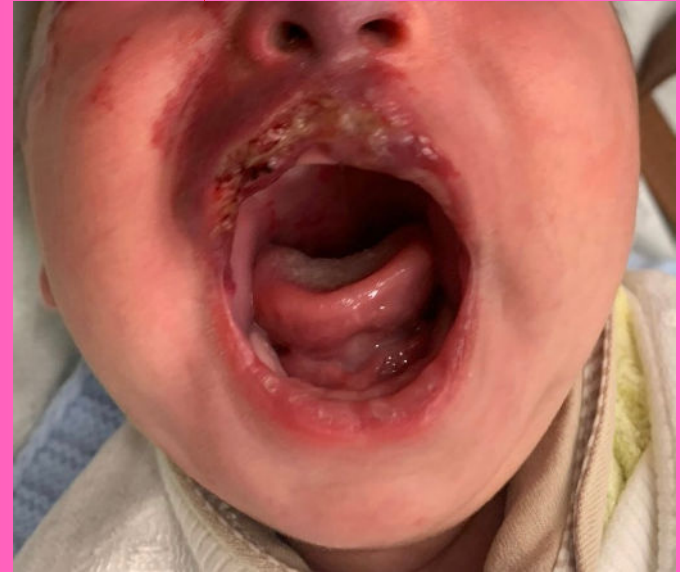A: Yes. If the lesion was only partially removed, it can recur, especially the NICH. She should have an ultrasound or other imaging done and then consider surgery.



Problems with Hemangiomas

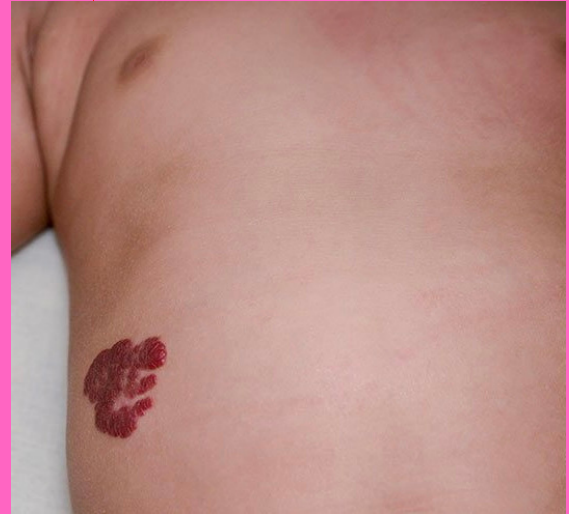Q: How do I treat my baby's ulcerated hemangioma? She is crying all the time. She is not on any treatments as our doctor told us it will go away on its own.

A: Most experts recommend a number of various combinations of treatments for ulcerated hemangiomas. Local wound care, continuation of beta blocker with the possible addition of steroids, and/or laser treatment may even be added. Sometimes the baby will need pain management drugs as well. Find an expert in IH management.



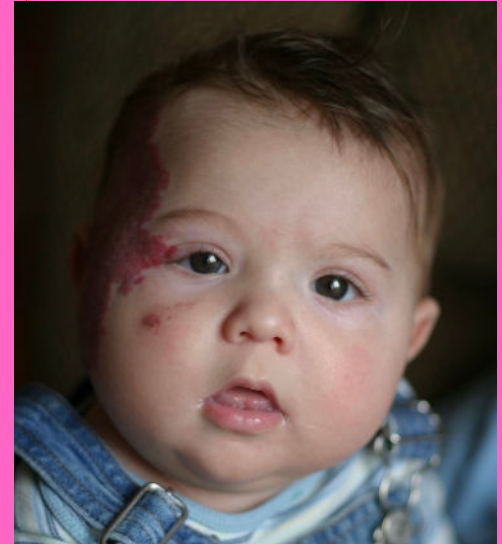Q: My baby is vomiting every time I give her the beta blocker. What should I do?

A: Not all babies respond positively to a generic beta blocker. You could try to switch to the FDA-approved Hemangeol or an off-label selective beta blocker. This has been reported as having less frequent adverse side effects. Or, you can seek other treatment options such as laser, surgery, or a combined steroid-beta blocker approach.



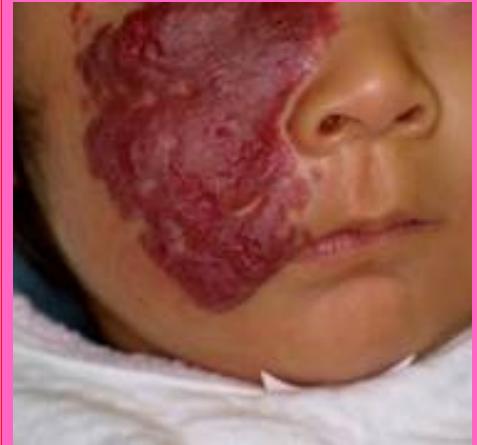Q: My baby skipped a day of their oral medicine. Should I double it?

A: Most experts suggest that you DO NOT double up on the meds if a dose is skipped or if the baby throws up the dose.



Q: My baby's hemangioma is getting worse on the beta blocker. Should I stop?

A: Sometimes the beta blocker can actually make the hemangioma worse. You can discontinue the drug or add steroids to the treatment plan. It may be important to confirm the diagnosis by seeing an expert and/or obtaining additional studies like imaging or biopsy to exclude other vascular tumors. You can also see an expert about possible laser treatment or even surgery.

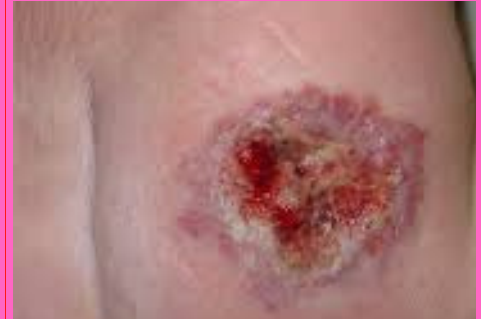

Q: My daughter had a laser treatment for her hemangioma when she was one week old. A few days later the entire side of her face ulcerated. Why did this happen? What should we do now?

A: Experts report that large segmental IH should not be lasered because they have seen them ulcerate. Wound care should be used until the ulceration has healed. At that point, you can look into other treatment options. The laser settings could also have been set too high. A lower setting treatment may actually help to clear up this ulceration.

Q: My son appears to be in pain from the hemangioma in his diaper area. Every time I change his diaper he cries. I'm putting timolol on it but it does not seem to be helping.

A: This is a very problematic area for babies. Timolol should not be used on open wounds. If the topical is not effective, the baby should be put on oral propranolol or steroids. You can also see if the baby is a candidate for a test spot with the laser since it is a sensitive area.



Q: My baby girl's hands keep turning blue and are freezing cold. This started soon after she began taking the beta blocker. Should we stop the drug? What are our options if we have to stop?

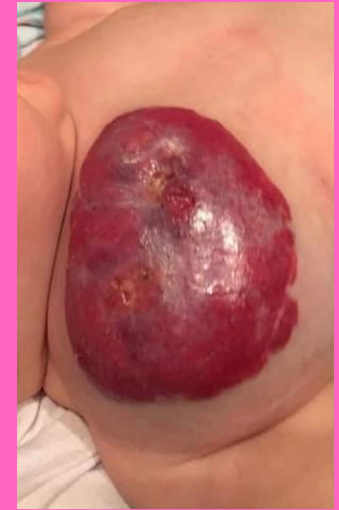
A: This is one of the most common reported side effects. Some experts suggest it is not harmful and others suggest the baby see a Pediatric Endocrinologist. In any event, it should not be ignored and other options should be explored, including selective beta blockers and oral steroids.

Q: My baby keeps vomiting and having diarrhea on the oral generic propranolol. I was told that Hemangeol has less negative side effects. Is that true? Is it the same thing as the generic?

A: Many parents report that babies who started on the generic and switched to Hemangeol had fewer side effects. The generic contains sugar and alcohol and Hemangeol does not. Again, selective beta blockers should also be considered.

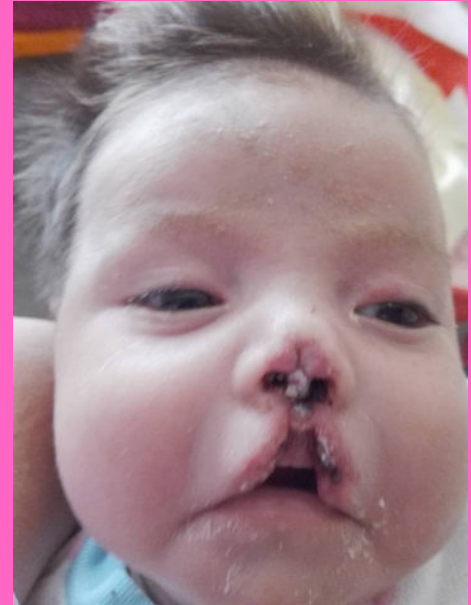Q: Our daughter is 2 and has a giant hemangioma on her breast, near her nipple. She keeps pulling on it and saying “Ouchy.” Does it hurt her? We were told to leave it alone because it could affect her breast later in life if we treat it or have it removed. What should we do?

A: That’s exactly the opposite of what should be done. Breast area IH should be treated immediately to prevent the breast tissue from reorganizing from the hemangioma involution process. This is especially true if it ulcerates. Early emerging breast area IH should be imaged early and treated promptly, if breast bud is involved.



Q: My baby's hemangioma is on her upper lip and it is ulcerated and she won't latch to feed. My baby's doctor gave me a special nipple for a baby bottle that is used for cleft palate babies. Why can't I breastfeed my baby? Why can't something be done to allow her to breastfeed?

A: First, the ulceration must be treated. Once this is treated, the baby may be able to resume breastfeeding. This is why it is important to treat early and aggressively if the IH is in a sensitive area like the mouth or the diaper area.



Q: I have fraternal twins, a boy and a girl. The boy has an ulcerated hemangioma near his anus and cries every time I clean him. I've been trying to leave his diaper off as much as possible. He's on Hemangeol but it is not getting better. Should we stop the Hemangeol? What can be done so he is not in pain?

A: As explained above, there are many options for treating an ulcerated IH. It is more difficult in the diaper area as it never gets the proper airing it needs. Wound care, pain management, and a barrier cream should be used, and the dose should be checked on the Hemangeol before deciding to discontinue it. This is a case where the addition of an oral steroid should be considered until the ulcerated area heals.


Q: There is a very large hemangioma covering my daughter's soft spot. It's bigger than a cherry tomato. I'm freaking out that it will bleed or grow down into her brain. My doctor said to leave it alone. What should I do?

A: Most of these IH that cover the fontanelle (soft spot) are not problematic and can resolve on their own. The hair usually grows in and can cover them, if it is not too large. A cherry tomato is a good size on a tiny baby's head so treatment should be considered with oral beta blocker since it sounds too large for timolol. Topical timolol only penetrates 1mm so it should not be used on any large focal lesions.



Q: On 4 occasions our daughter's forehead hemangioma bled for a long time. She is on Hemangeol, and it shrunk quite a bit from the drug, but there is still some there and she keeps bumping it and making it bleed. We keep taking her to the ER. She is almost a year old.

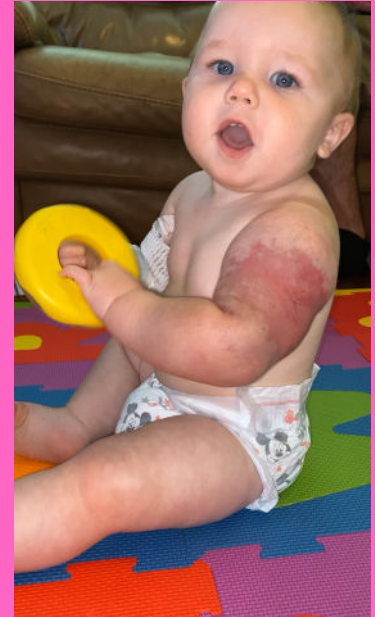A: This is a perfect example of an IH that should be surgically removed, if at all possible. She's been on the beta blocker and yet she keeps bumping it and bleeding and you keep going to the ER. See an expert surgeon who removes IH.



Kaposiform Hemangioendothelioma (KHE)

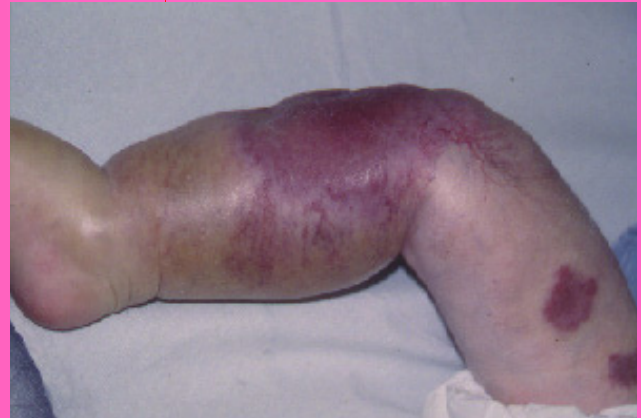Q: What is KHE?

A: KHE is neither an Infantile Hemangioma nor is it a Congenital Hemangioma such as the NICH, RICH, and PICH. It is a rare benign tumor that often looks like a CH and sometimes looks like an IH, so it is often misdiagnosed. This can be a serious problem as KHE can become life-threatening if not treated. KHE often presents as a large, dark red/blue/purple lesion that is usually bulky but sometimes it can be flat and infiltrate the deep underlying tissue. It is very warm to the touch. It can appear at or shortly after birth. Some can actually appear later in life. It can look quite alarming but sometimes it can look quite innocent. While these lesions are NOT cancerous, the KHE tumors can become problematic and result in a serious drop in platelets and fibrinogen levels. The best way to describe KHE is that it looks very angry and dark red/blue or purple in color. These lesions are also GLUT1 negative, just like a CH but unlike an IH which is GLUT1 positive.



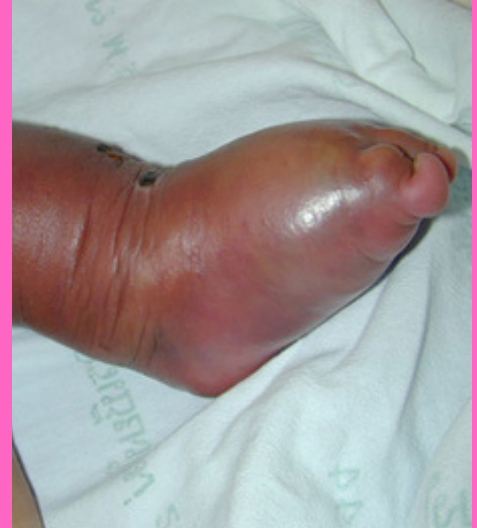Q: What is the treatment for KHE?

A: Often, combinations of drug therapies such as vincristine, steroids, and/or sirolimus, and aspirin, plus surgery, or an interventional approach is used. If it is on an extremity, it is not unusual to use a tight compression wrapping to choke off the high flow. Some really small KHE cases can be observed. However, if platelets and fibrinogen levels are abnormally low, treatment is urgent.



Q: Does KHE go away totally or can it recur later in life?

A: KHE, after treatment, usually regress, but they can remain inactive for decades and then suddenly become active again. There are so few cases that it is really difficult to know how these will progress.



Q: What are the chances of another pregnancy resulting in KHE?

A: These are one of the rarest of all vascular anomalies and there is no data to support occurrence in subsequent births. There is also no information to suggest it is familial (runs in families).



About the Authors



Dr. Linda Rozell-Shannon, PhD
President/Founder
Vascular Birthmarks Foundation



Dr. Bernard Cohen, MD
Pediatric Laser Expert



Dr. Ana Duarte, MD, FAAD
Pediatric Dermatology Expert



Dr. Milton Waner, MD, MBBCh, FCS(SA)
Hemangioma and Malformations Expert