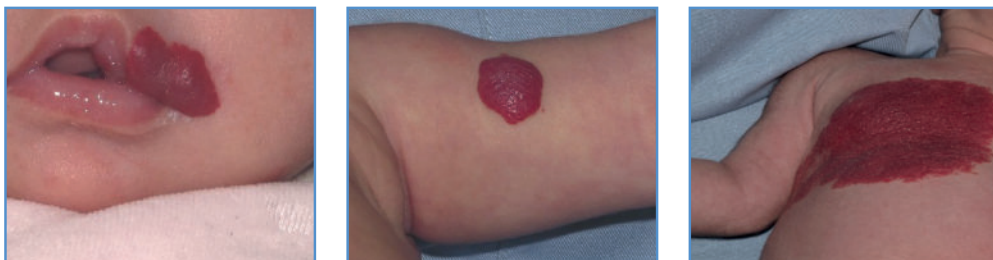

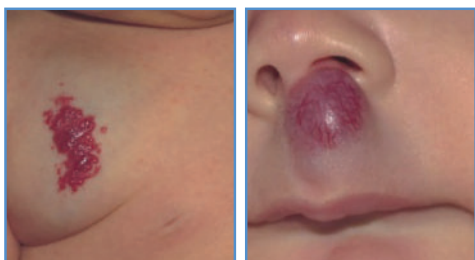INFANTILE HEMANGIOMA

3 TYPES of Infantile Hemangioma (1)

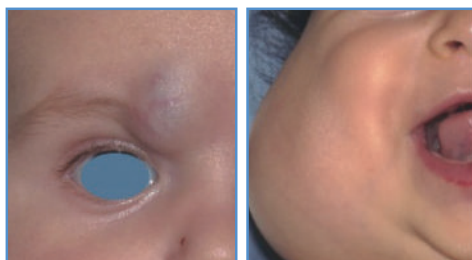
SUPERFICIAL IH



MIXED/COMBINED IH



SUBCUTANEOUS/DEEP IH

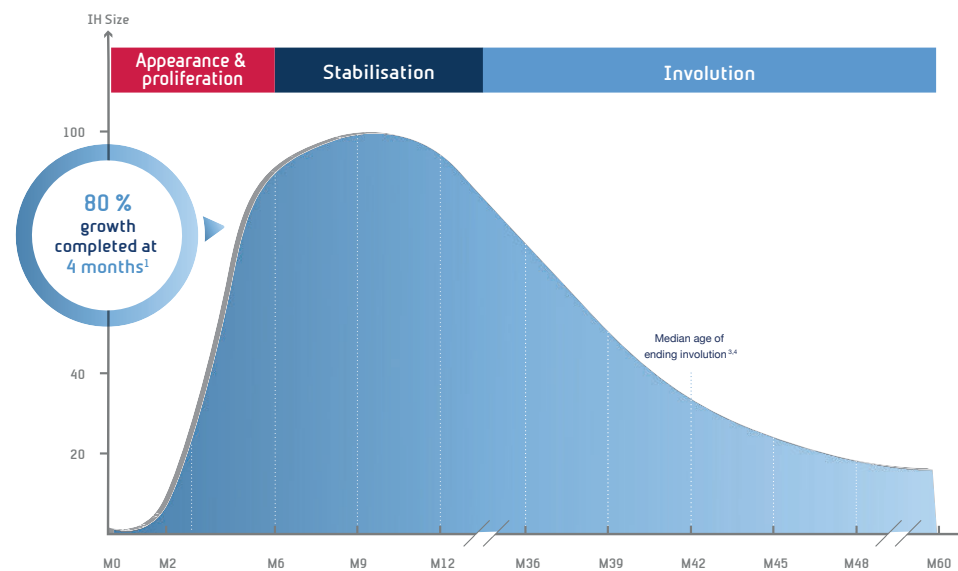


“
5% of infants
below the age
of 1 year^{2,5,6}
”



DISEASE EVOLUTION (2)

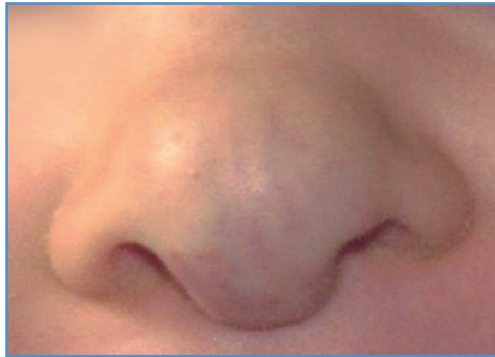
3 PHASES



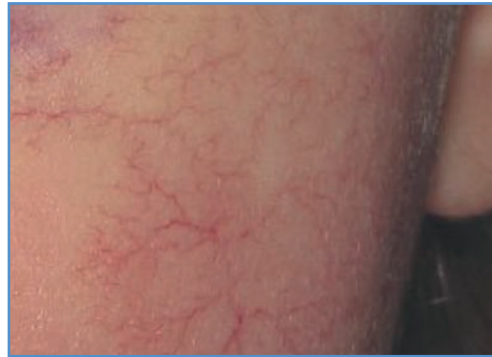INFANTILE HEMANGIOMA

SEQUELAE AFTER INVOLUTION OF UNTREATED HEMANGIOMAS (3-4)

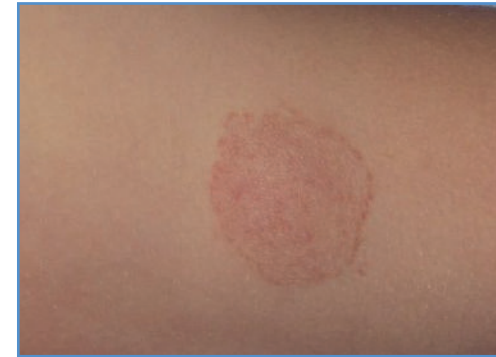Anatomic Distortion



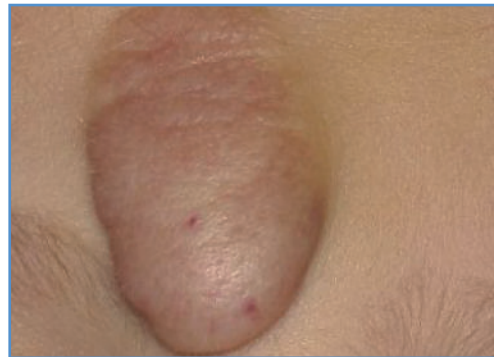Telangiectasias



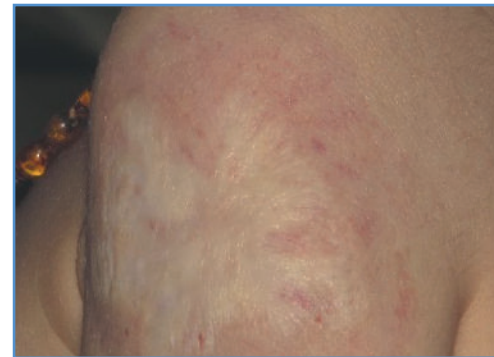Anetodermia/Redundant skin



Fibrofatty Tissue



Scar



1. Leauté-Labrèze C, Prey S, Ezzedine K. Infantile haemangioma: Part I. Pathophysiology, epidemiology, clinical features, life cycle and associated structural abnormalities. *J Eur Acad Dermatol Venereol.* 2011 Nov;25(11):1245-53.
 2. Leauté-Labrèze C, Harper JI, Hoeger PH. Infantile haemangioma. *The Lancet.* 2017 Jul;390(10089):85-94.
 3. Darrow D, Greene AK, Mancini AJ, Nopper A J. Diagnosis and Management of Infantile Hemangioma. *PEDIATRICS.* 2015 Oct;136(4):1060-1104.
 4. Baselga E, Roe E, Coulie J, Munoz Fania Z, Boon LM, McCuaig C et al. Risk Factors for Degree and Type of Sequelae After Involution of Untreated Hemangiomas of Infancy. *JAMA Dermatol.* 2016 Nov;152(11):1239-1243.
 5. Munden et al – Incidence and demographics of IH – *BJD* 2014, 170; 907-913
 6. Volc-Platzer et al. – Poster ESPD 2014 – 4. Chen et al. Update on pathogenesis and therapy. *Pediatrics.* 2012
- Pictures source: PFD internal images bank

Pierre Fabre | SKIN EXPERTISE
DERMATOLOGIE | IN OUR DNA