

A close-up photograph of a baby's face, looking directly at the camera. The baby has light brown hair and blue eyes. On the upper right side of the forehead, there is a prominent, raised, red, and somewhat irregular lesion, characteristic of an infantile hemangioma. The baby's hands are resting under their chin. The background is a plain, light color.

—
INFANTILE HEMANGIOMA
—

What is an ?
infantile hemangioma

DOCUMENT PRODUCED IN COLLABORATION WITH
PEDIATRICIANS, DERMATOLOGISTS AND PARENTS

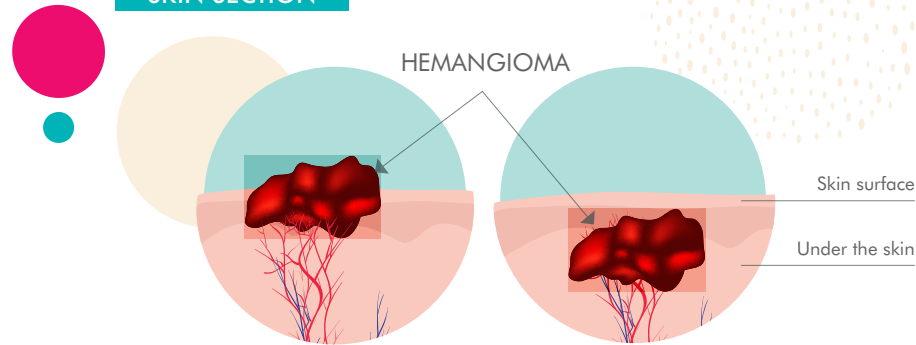
WHAT IS AN INFANTILE HEMANGIOMA?

- Infantile hemangioma is an overgrowth of blood vessels in the skin.
- The proliferation of the vessels occurs at varying depths under the skin.

It is **the most common vascular lesion in infants**: 4.5% of infants under 1 year of age^{1,2,4} are affected, and it is even more common in children born prematurely³.

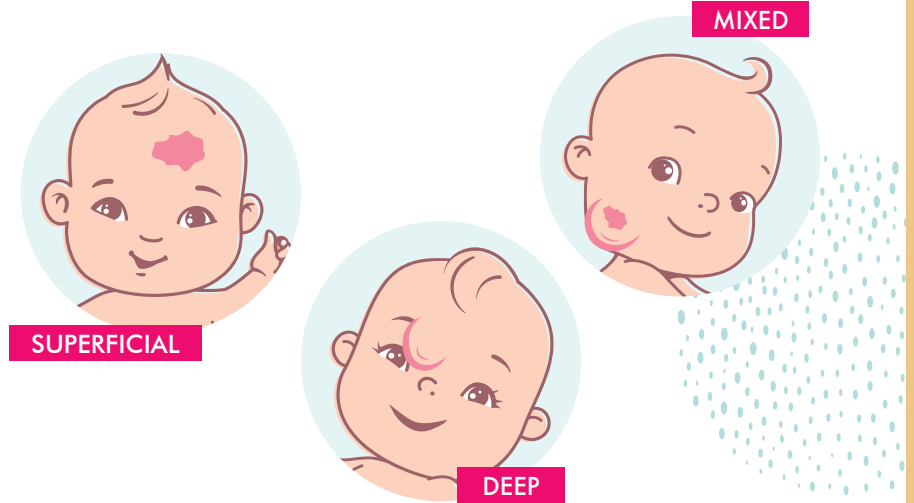
4.5% OF INFANTS
UNDER 1 YEAR OF AGE
ARE AFFECTED

SKIN SECTION



1. Léauté-Labreze et al – Infantile Haemangioma –Lancet 2017 Jul 1;390 (10089): 85-94
2. Munden et al – Incidence and demographics of IH – BJD 2014, 170; 907-913
3. Goelz R et al. Incidence and treatment of infantile hemangioma in preterm infants. Arch Dis Child Fetal Neonatal Ed 2015; 100 F85-91
4. Volc-Platzter et al. – Poster ESPD 2014

THERE ARE 3 TYPES OF INFANTILE HEMANGIOMAS:
SUPERFICIAL, DEEP OR MIXED



WHY ARE SOME BABIES MORE AT RISK OF DEVELOPING AN INFANTILE HEMANGIOMA?

Among the known risk factors, the most common are:

- Very premature birth
- Multiple pregnancy
- Pregnancy with complications such as placental abnormalities or high blood pressure



WHY SHOULD YOU CONSULT A DOCTOR?

AS SOON AS A LESION APPEARS, DO NOT HESITATE TO CONSULT A GENERAL PRACTITIONER OR A PEDIATRICIAN, WHO WILL KEEP AN EYE ON THE HEMANGIOMA.

In the vast majority of cases, infantile hemangiomas do not present any complications and disappear on their own.

For **1 hemangioma out of 10**
a specialized opinion is necessary.



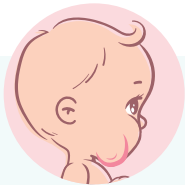For a little more than one hemangioma out of 10, a specialized opinion is required because of a risk of complications:

- A risk of scarring, especially on the face.
- A risk of bleeding from the hemangioma.
- An impact on vision, or feeding or respiratory problems.

In these cases, early treatment of your child's hemangioma is critical. Your child should be referred by your doctor to an infantile hemangioma specialist. The latter will opt for specific treatment or put in place a very regular monitoring.

WHAT ABOUT THE RISKS OF AFTER-EFFECTS?***

Early treatment of your child's hemangioma is critical. An untreated hemangioma can lead to after-effects that are sometimes difficult to reverse.




Fibrofatty tissue



Telangiectasia



Anatomic distortion



Residual scarring

IMPACT ON FAMILY LIFE*

Because of their early onset and rapid evolution, infantile hemangiomas can sometimes have a psychological impact that must be taken into account by parents. Other people staring can be difficult to bear, regardless of the type of infantile hemangioma. In some cases, this can create anxiety, with repercussions on family life.



IT IS IMPORTANT TO TALK ABOUT IT WITH YOUR DOCTOR OR PEDIATRICIAN.

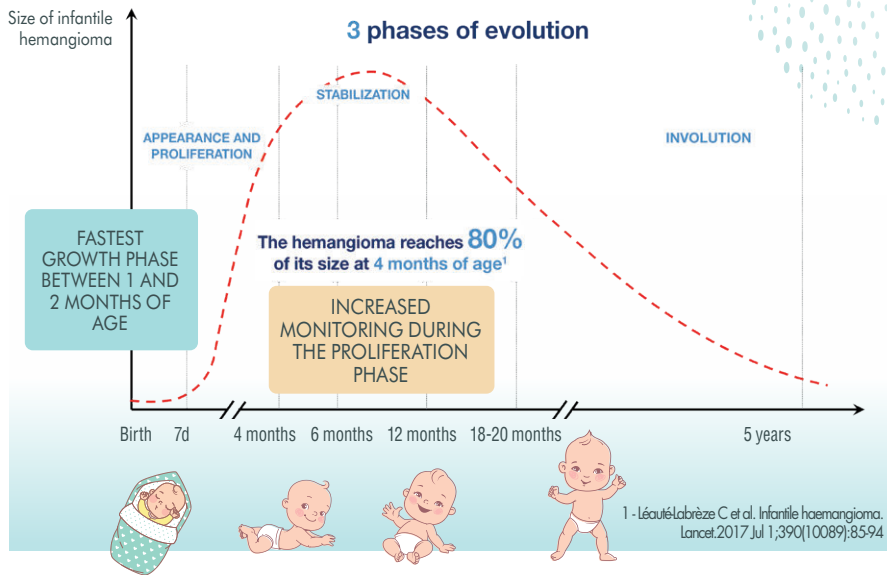
*** Darrow D, Greene AK, Mancini AJ, Nopper A J. Diagnosis and Management of Infantile Hemangioma. PEDIATRICS. 2015 Oct;136(4):1060-1104.4 - Baselga E, Roe E, Coulie J, Munoz Fania Z, Boon LM, McCuaig C et al. Risk Factors for Degree and Type of Sequelae After Involution of Untreated Hemangiomas of Infancy. JAMA Dermatol. 2016 Nov;152(11):1239-1243.

* Cazeau C, Blei F, González Hermosa MDRF, Covalli R, Boccara O, Følster-Holst R, Berdeaux G, Delarue A, Voisard JJ. Burden of Infantile Hemangioma on Family: An International Observational Cross-Sectional Study. Pediatr Dermatol. 2017 May;34(3):295-302. doi: 10.1111/pde.13133. Epub 2017 Apr 6.

WHEN SHOULD YOU CONSULT A DOCTOR?

- Infantile hemangioma is usually not present at birth but appears in the first days or weeks of life.
- Warning signs may be present in approximately 50% of cases. These signs take the form of either a pinkish-red blotch or a white mark.

NATURAL EVOLUTION OF INFANTILE HEMANGIOMA



!!!

AS SOON AS AN INFANTILE HEMANGIOMA APPEARS, IT IS VITAL TO CONSULT A PEDIATRICIAN OR DOCTOR.

Increased monitoring during the proliferation phase is important. The pediatrician or doctor will arrange for regular follow-up visits or refer your child to a doctor with expertise in infantile hemangiomas.

Do not hesitate to report any changes in the size or appearance of the infantile hemangioma to your doctor. The earlier it is treated, the more likely it is to disappear quickly and without any after-effects.



It may be helpful to take pictures of your child's hemangioma regularly so that your doctor can more easily monitor its progress.

HOW IS THE DIAGNOSIS MADE?

The diagnosis and determination of the degree of severity of the infantile hemangioma are made during the clinical examination.

Your doctor or the pediatric hemangioma expert will assess the severity of the hemangioma by considering:

- Your child's age
- The number and location of the hemangioma(s)
- The size of the hemangioma and its appearance (color, thickness, etc.)

- Its evolution: is the hemangioma growing or stable? Photos of your child since birth can be of great help.

In some cases, the doctor may need to perform additional tests (medical ultrasound, MRI scan, etc.) to confirm the diagnosis.

HOW IS AN INFANTILE HEMANGIOMA TREATED?

Depending on the type of hemangioma, the expert treating your child may use different treatment protocols such as:

- Medicinal treatment
- Laser therapy
- Surgery



Also known as “strawberry birthmarks”, infantile hemangiomas are often the subject of questions from little patients and their big brother(s), sister(s) and friends. To help you explain everything to your child:

CHECK OUT

“MARY THE MOUSE HAS AN INFANTILE HEMANGIOMA”

